

Three-Vessel View

Figure 1 - Normal

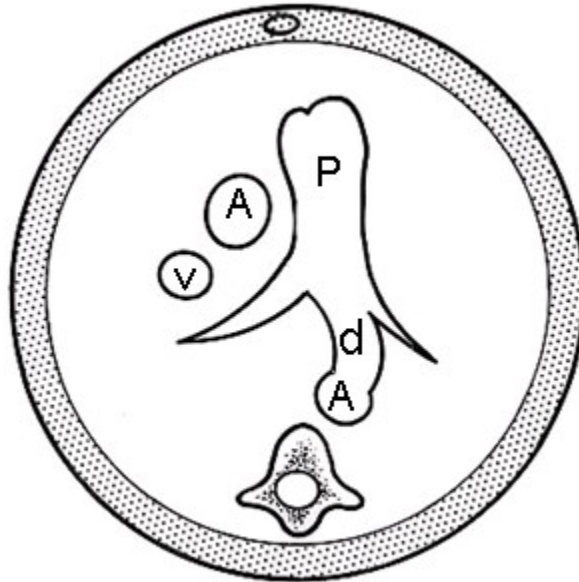


Figure 2- Abnormal, Tetralogy of Fallot

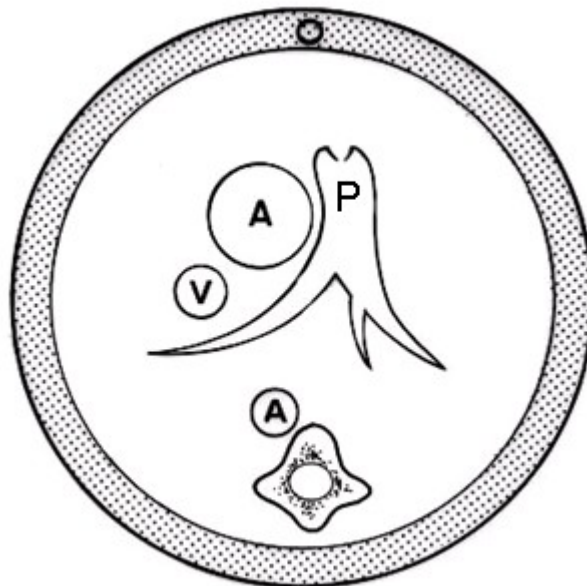


Figure 3 - Abnormal, Complete Transposition

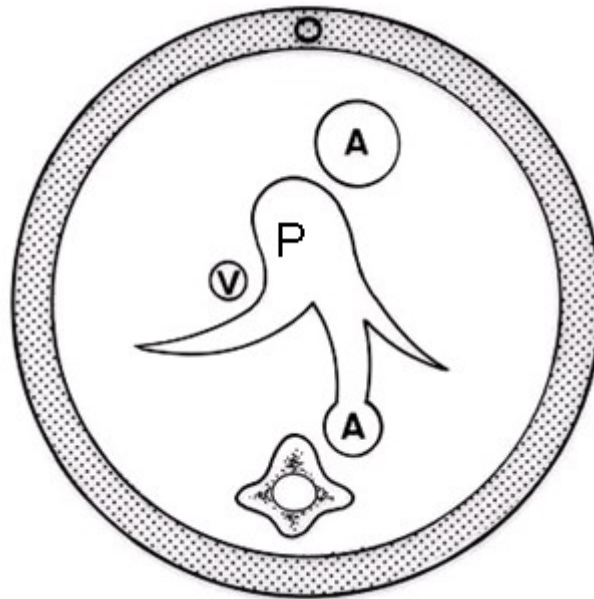


Figure 4 - Abnormal, Corrected Transposition

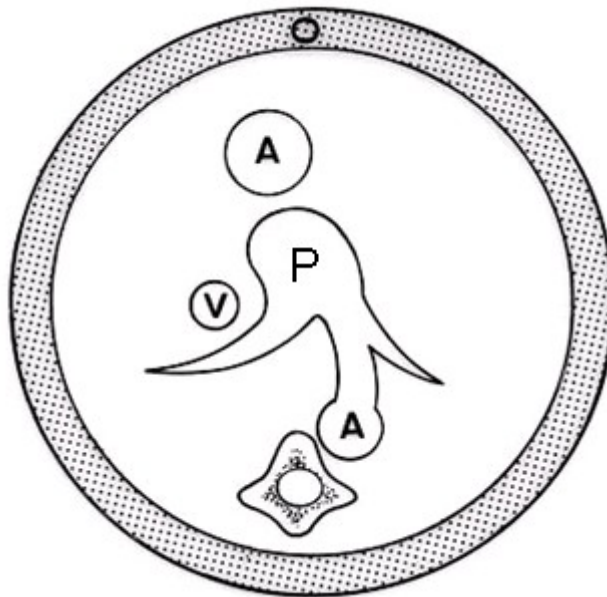


Figure 5 - Bilateral Superior Vena Cava

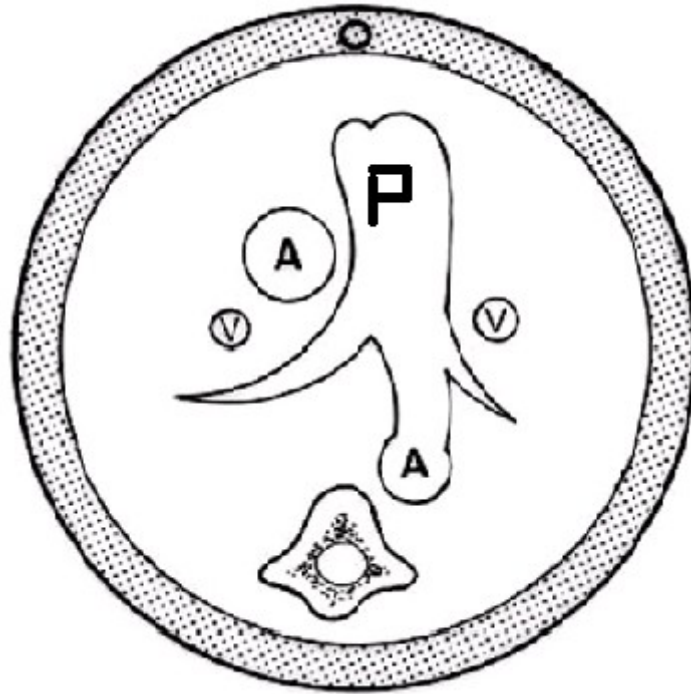

Figure 6 - Abnormal, Left side Obstruction (HLHS)

